

## VARIANTS OF THE CIRCLE OF WILLIS ON NON-CONTRAST MAGNETIC RESONANCE ANGIOGRAPHY

*Lam Buu Nguyet\**, *Nguyen Hoang Thuan*, *Nguyen Truong Tho*,  
*Nguyen Vinh Quang*, *Huynh Huu Phuc*, *Nguyen Phuong Thao*  
Can Tho University of Medicine and Pharmacy

\*Corresponding author: [lambuunguyet@gmail.com](mailto:lambuunguyet@gmail.com)

### ABSTRACT

**Background:** The Circle of Willis (CoW) distributes oxygenated blood throughout the brain and represents the only major anastomosis of the brain. The study of variations in CoW is crucial for avoiding confusion of the anomalies with aneurysms, evaluating collateral pathways in the intracerebral circulation, and enhancing pre-operative planning in patients undergoing surgery at the skull base. **Objectives:** Evaluate and describe the prevalence of variations of the CoW by using three-dimensional time-of-flight MR angiography (3D-TOF-MRA). **Materials and methods:** We conducted a cross-sectional description in 102 patients after meeting the requirements of inclusion criteria. All participants were scanned in a GE Optima 360 1.5T MRI scanner. The variants of the CoW were studied. The correlation between variations in relation to gender and age were evaluated. **Results:** Among 102 samples, the mean age was 46, and female dominance was seen among participants (60.80%). The proportion of CoW with normal shape (7 edges) as in classical anatomy is 10.78%. The highest prevalence of variations was seen in PCOM-R with 62.75% (64/102) and PCOM-L with 58.82% (60/102). We recorded 32 types of CoW variation, including 7 single variants accounting for 26.37% (24/91) and 25 combined variants with 73.63% (67/91), some of which had not been reported in previous studies. **Conclusion:** The complete configuration of the CoW was seen in 10.78% of population. 32 types of CoW variation, including 7 single variants (26.37%) and 25 combined variants (73.63%) were recorded.

**Keywords:** Circle of Willis, Magnetic resonance 3D-time of flight angiography, anatomical variations.

## I. INTRODUCTION

Depending on the amount of blood supply to various areas of the brain, the circle of Willis (CoW), also known as the cerebral arterial circle, is divided into anterior and posterior portions. While the former is contributed by carotid arteries and their branches, the latter is contributed by the vertebrobasilar system [1]. The CoW distributes oxygenated blood throughout the brain and represents the only major anastomosis of the brain. Therefore, it has been studied in many medical specialties due to great importance. When thrombus formation occurs and partially obstructs cerebral blood flow, other arteries aid in maintaining cerebral perfusion through the CoW, which prevents sufficiently the onset of symptoms of ischemia.

Numerous earlier research conducted in the world, including in Vietnam, have reported on the anatomical variances of the circle of Willis. There have been detected to be dimensional variations such as hypoplasia, absence, or morphologic variations like duplication, fenestration, etc. They may show up individually (Single variant) or collectively (Combined variant) [10]. Over 60% of the population exhibits morphologic variations of CoW, and about 32.2% of the general population has complete CoW [10]. The study of variations is crucial for avoiding confusion of the anomalies with aneurysms, evaluating collateral pathways in the intracerebral circulation, and enhancing pre-operative planning in patients undergoing surgery at the skull base [6].

The objective of this study is to evaluate and describe the prevalence of variations of the CoW by using three-dimensional time-of-flight MR angiography (3D-TOF-MRA).

## II. MATERIALS AND METHODS

### 2.1. Research subjects

The study was conducted on patients with indications for brain MRI at the Diagnostic Imaging Department of Can Tho University of Medicine and Pharmacy Hospital.

### 2.2. Research methods

**Research design:** A cross-sectional description study was conducted.

**Sample size:** The study included 102 patients after meeting the requirements of inclusion criteria.

**Sampling method:** Convenience sampling. Patients who had cerebrovascular diseases that damage to the arterial lumen of the CoW such as ischemic stroke, intracerebral hemorrhage, arteriovenous malformations, brain tumors, intracranial aneurysm... or conducting any neurosurgeries before would be excluded. Then, the participants were scanned in a GE Optima 360 1.5T MRI scanner (Can Tho University of Medicine and Pharmacy Hospital, Can Tho, Vietnam) from July 2021 to September 2022. After excluding substandard samples and obtaining approval from the Medical Ethics Committee, we collected a total of 102 MRI image files and patient information.

### **Research content:**

After taking samples, the classification of CoW variants TOF images were evaluated by all research fellows individually, using a program created in RadiAnt DICOM Viewer (v2021.2.2). Scanning was done with following parameters: TR/TE/FA (28.0/3.6/1.5), slice

thickness of 1.2 mm. The program displays the TOF images both as a 3D rendering or a maximum intensity projection (MIP), and in 2D with a lumen diameter measurement tool. When consensus was reached, it then was processed and used for statistical analysis. The Chi-Square test of independence has been used to find out correlation where needed. All the p values <0.05 considered as statistically significant.

A total of seven major arteries of the CoW were considered in our variants. These are the left and right proximal anterior cerebral artery (A1-L and A1-R), the anterior communicating artery (ACOM), the left and right posterior communicating artery (PCOM-L and PCOM-R), and the left and right proximal posterior cerebral artery (P1-L and P1-R). In this study, we categorize the CoW variation into four types: hypoplasia, aplasia, duplication and fenestration. Single variation includes one of the four variants and occurs in only one artery branch. Combined variation can include one or more variant types and occur in two or more branches.

### III. RESULTS

#### Study participants

This study was conducted in 102 samples. Among them, females took the majority with 60.80% (62/102) while male participants were 39.20% (40/102). The mean age was  $46.28 \pm 14.05$ , the oldest participant was 73 and the youngest one was 11. The age group of 19-60 was predominantly seen with 84.30% (86/102). There is only 1 case recorded in the age group of 0-18, accounting for the lowest rate with 1%.

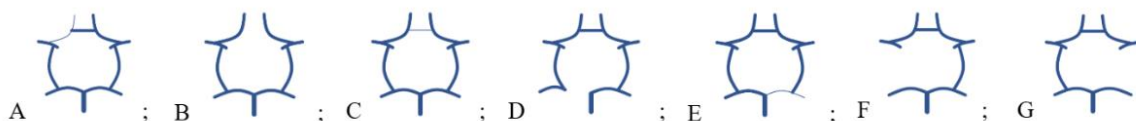#### Prevalence of variations in the Circle of Willis

**Table 1.** Prevalence of variations in the Circle of Willis according to age and gender

	Total	Complete N %	Single variants N %	Combined variants N %
<b>Gender</b>				
Male	40	2 5.00%	9 22.50%	29 72.50%
Female	62	9 14.52%	15 24.19%	38 61.29%
p>0.05				
<b>Age in years</b>				
<=18	1	0 0.00%	1 100.00%	0 0.00%
19-60	86	11 12.79%	20 23.26%	55 63.95%
>60	15	0 0.00%	3 20.00%	12 80.00%
p>0.05				

As demonstrated in Table 1, the combined variants accounted for 73.63% (67/91), and the single variants accounted for 26.37% (24/91). Our study noted that the prevalence of variation in males accounting for 95% (38/40) was higher than that of females accounting for 85.48% (53/62), in which combined variations in males accounted for the highest rate with 72.5% (29/40). When comparing the ages, the prevalence of variations was recorded

in the age group  $\leq 18$  and  $> 60$  for 100%, and the combined variants accounted for the highest rate in all age groups. However, these values are not statistically significant ( $p > 0.05$ ).



**Figure 1.** Single variants in the Circle of Willis

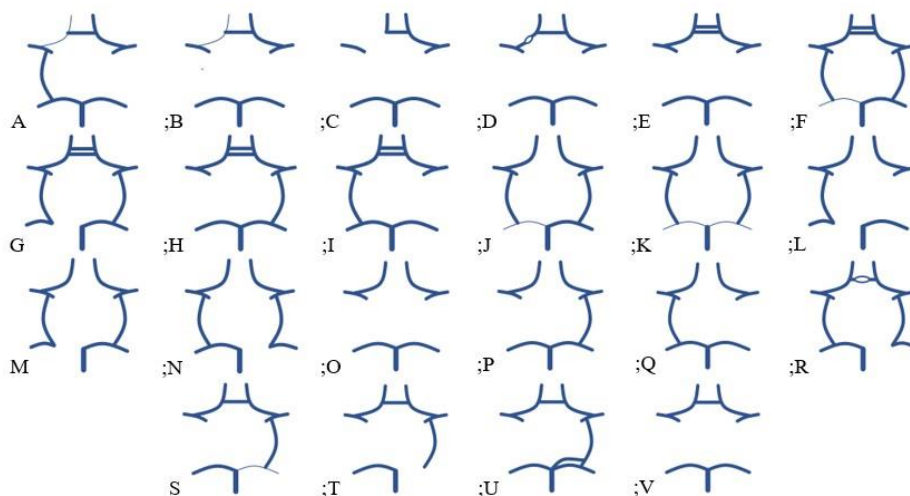
(A) A1-R hypoplasia; (B) ACOM aplasia; (C) ACOM hypoplasia; (D) P1-R aplasia; (E) P1-L hypoplasia; (F) PCOM-R aplasia; (G) PCOM-L aplasia.

Figure 1 showed 7 single variants, which were recorded in 24 cases, accounting for 26.37% (24/91) out of all cases having variation. In our study, the single variation only included changes in dimension (hypoplasia and aplasia). The morphologic changes were not recorded in single variation.

**Table 2.** Prevalence of single variants

Variants	A	B	C	D	E	F	G
No. of participants (n=24)	2	2	1	1	1	11	6
Percentage (23.53%)	1.96%	1.96%	0.98%	0.98%	0.98%	10.78%	5.88%

The table showed that among 7 single variants detected in our study, the most common type was PCOM-R aplasia (F), accounting for 10.78% (11/102), followed by PCOM-L aplasia (G) with the rate almost half lower (5.88%). The remaining variants appeared in insignificant proportion, less than 2%.



**Figure 2.** Combined variants in the Circle of Willis

(A) A1 hypoplasia + PCOM-L aplasia; (B) A1 hypoplasia + PCOM-L aplasia + PCOM-R aplasia; (C) A1 aplasia + PCOM-L aplasia + PCOM-R aplasia; (D) A1-R fenestrations + PCOM-R aplasia + PCOM-L aplasia; (E) ACOM duplications + PCOM-R aplasia + PCOM-L aplasia; (F) ACOM duplications + P1-R hypoplasia; (G) ACOM duplications + P1-R aplasia; (H) ACOM duplications + PCOM-R aplasia; (I) ACOM duplications + PCOM-L aplasia; (J) ACOM aplasia + P1-R

hypoplasia; (K) ACOM aplasia + P1-R hypoplasia + P1-L hypoplasia; (L) ACOM aplasia + P1-R aplasia + PCOM-L aplasia; (M) ACOM aplasia + P1-R aplasia; (N) ACOM aplasia + P1-L aplasia; (O) ACOM aplasia + PCOM-R aplasia + PCOM-L aplasia; (P) ACOM aplasia + PCOM-R aplasia; (Q) ACOM aplasia + PCOM-L aplasia; (R) ACOM fenestrations + P1-L aplasia; (S) P1-L hypoplasia + PCOM-R aplasia; (T) P1-L aplasia + PCOM-R aplasia; (U) P1-L duplications + PCOM-R aplasia; (V) PCOM-R aplasia + PCOM-L aplasia.

Out of 102 surveyed subjects, there were 67 cases with combined variants (73.63%), including 63 cases related to the 4 types of variation, which was divided into 22 types, and 4 cases of other variants. Figure 2 described 22 types of combined variants, some cases having up to 3 changes.

**Table 3.** Prevalence of combined variants

Variants	A	B	C	D	E	F	G	H	I	J	K
No. of participants (n=63)	1	2	1	1	5	1	1	1	1	1	1
Percentage (64.71%)	0.98 %	1.96 %	0.98 %	0.98 %	4.90 %	0.98 %	0.98 %	0.98 %	0.98 %	0.98 %	0.98 %
Variants	L	M	N	O	P	Q	R	S	T	U	V
No. of participants (n=63)	1	1	1	9	1	3	1	1	1	1	27
Percentage (64.71%)	0.98 %	0.98 %	0.98 %	8.82 %	0.98 %	2.94 %	0.98 %	0.98 %	0.98 %	0.98 %	26.47 %

The table showed that among the combined variations, the most common one is PCOM-R aplasia + PCOM-L aplasia (V) with 27 out of 63 reported cases, accounting for 26.47%. However, the remaining 2-branch variations only have 1 to 5 cases.

**Other variants**

There were 3 other variants, which were not mentioned in the 4 types of variation, that appeared in 4 cases. We also categorized these as combined variants, cause the variations appeared in two or more branches. In these types, 1 form has appeared in other studies, and 2 new ones have not been described before. The first type is “Fusion of the anterior cerebral artery occurs over a short distance” with 2 cases (1.96%). Next, we noticed that “2/3 A2 segments of trifurcation of the anterior cerebral artery arise from the same A1 segment” with 1 case (0.98%). Finally, the “True fetal posterior cerebral artery is connected by a short distance to the posterior communicating artery” with 1 case (0.98%).

**IV. DISCUSSION**

**Single variants**

To facilitate comparison and contrast with other studies, we re-divided the recorded single variants into 6 types, accounting for 26.37% (24/91) including: one-sided A1 hypoplasia, ACOM aplasia, ACOM hypoplasia, one-sided P1 aplasia, one-sided P1 hypoplasia, one-sided PCOM aplasia.

In terms of dimensional variation, in the anterior part, our study and Nguyen Tuan Son’s [10] both have nearly the same results, except for the prevalence of ACOM aplasia, which is nearly double our study. On the other hand, Li’s [8], Mai Thi Hue’s [5] and

Kızılgöz's [7] study recorded the one-sided A1 aplasia variant, accounting for 1.88% (3/160), 2.22% (3/135) and 2.88% (25/897) respectively, which was not seen in our study and Son's study. Kızılgöz's [7] percentage of ACOM aplasia is especially higher than other researches, occupying 16.49% (143/897).

For the posterior part, our research found that the one-sided PCOM hypoplasia variant, makes up about 16.67% (17/102), almost equal to Nguyen Tuan Son's study [10] at 12.64% (33/261) and Kızılgöz's [7] at 16.15% (140/897), but we did not detect the hypoplastic form of PCOM.

Our study did not record any single morphologic change, this conflict may be due to our study using magnetic resonance imaging instead of computed tomographic scan like the other studies, as well as the sample size was not large enough to cover up all the variants of Willis' circle.

### **Combined variants**

Our study recorded that out of 91 different variations, there were 67 cases (4 other types included) with combined variants accounting for 73.63%. 63 cases related to dimensional and morphologic variation were divided into 22 types. According to Nguyen Tuan Son [10], combined variants had 40 cases out of a total of 58 variants, accounting for 69% (40/58). According to Mai Thi Hue [5], combined variants had 9 cases out of 25 variants (36%). In which the two authors agreed with us that the most common combined variant was bilateral PCOM aplasia, comprising 8% (21/261) and 23.53% (32/135) respectively. Some cases had up to 3 variants in our research, while in Son's one had up to 5 changes. Mai Thi Hue approached one-sided and two-sided variants of the cerebral arteries, so our results could not be compared with theirs.

According to Lars B. Hindenes [4] and Volkan Kızılgöz [7], the authors also showed that the most common variant was bilateral PCOM aplasia with the rate of 27.8% (518/1864) and 27.57% (239/867), respectively. In Enyedi's study [3], the most common variant was unilateral PCOM aplasia with 22.22% (28/126), but this rate only considers variation in the posterior part, while the most common combined variant was still bilateral PCOM aplasia with 15.9%. The data mentioned above are quite similar to the rate of bilateral PCOM aplasia (26.47%) in our study. Volkan Kızılgöz and M. Enyedi approached variations by anterior and posterior parts, so comparisons of proportions with our study would not be accurate.

In summary, the 5 authors Nguyen Tuan Son, Mai Thi Hue, Volkan Kızılgöz, M. Enyedi and Lars B. Hindenes agreed with our study on the most common type of combined variants, bilateral PCOM aplasia. Our research had an almost similar result to Volkan Kızılgöz and Lars B. Hindenes, which firmly consolidated with ours. The other authors encountered a much lower rate of this type of variation, this may be due to different research facilities as well as dissimilar sample sizes.

### **Other variants**

Our research has recorded 3 other variants, which were not associated with the 4 types of variation: Fusion of the anterior cerebral artery occurs over a short distance (1); 2/3 A2 segments of trifurcation of the anterior cerebral artery arise from the same A1 segment (2); True fetal posterior cerebral artery is connected by a short distance to the posterior communicating artery (3).

For type (1), the variant occurred in ACOM when the anterior cerebral arteries formed a short common stem and split into two A2 segments. This was a type D variant of the anterior segment of the Willis polygon as described by Shatri Jeton [9].

For type (2), A2 showed as a three-vessel, but two of the three stems originated from the same A1. This type of variant was quite similar to the C and H variants according to Shatri Jeton [9], but some differences still existed. It differs from type C in that the medial artery of the corpus callosum does not arise from ACOM but from a pre-communicating segment of an anterior cerebral artery, which differs from type H in the pre-communicating segment without hypoplasia or aplasia.

For type (3), the true fetal posterior cerebral artery, as described by Bruno Coulier [2], had two independent posterior cerebral arteries present. A posterior cerebral artery (usually more popular) arose from a large primary anterior choroidal artery and a second (usually the smaller) posterior cerebral artery developed in a conventional manner. However, according to Bruno Coulier [2], the two later cerebral arteries were independent of each other, and in our study, these two circuits were connected by a short distance.

## V. CONCLUSIONS

Our study was carried out on 102 subjects undergoing brain MRI at the Can Tho University of Medicine and Pharmacy Hospital, of which females accounted for 60.8% (62/102), and the male/female ratio was 1/1.55. The age group 19-60 accounted for the most in the study with 84.3% (86/102). The proportion of the cerebral arterial circle with normal shape (7 edges) as in the textbook was 10.78%. Our study recorded 32 types of Circle of Willis variation, including 7 types of single variation and 25 types of combined variation, some of which had not been reported in previous studies. The percentage of the cerebral arterial circle with variation in one component (single variant) was 26.37%; with variation in many components (combined variant) is 73.63%.

## REFERENCES

1. Amjad, Marium & Maryam, Sarah & Zakir, Muhammad, et al. (2022), Different anatomical variations of circle of Willis in adult patients on magnetic resonance angiography, *Pakistan Journal of Medical and Health Sciences*, 16, pp. 183-185.
2. Coulier, B. (2018), Duplication of the Posterior Cerebral Artery (PCA) or “True Fetal PCA”: An Extremely Rare Variant, *Journal of the Belgian Society of Radiology*, 102(1), pp. 1-2.
3. Enyedi M, Scheau C, Baz RO, and et al. (2021), Circle of Willis: anatomical variations of configuration. A magnetic resonance angiography study, *Folia morphologica*.
4. Hindenes LB, Håberg AK, Johnsen LH, Mathiesen EB, Robben D, et al. (2020), Variations in the Circle of Willis in a large population sample using 3D TOF angiography: The Tromsø Study, *Plos One*, 15(11).
5. Hue, Mai Thi (2018), *The characteristics of the circle of Willis on multidetector CT angiography in humans without cerebral vascular malformations*, Graduate dissertation, pp. 27-37.
6. Keeranghat, P. P., & Jagadeesan, D. (2018), Evaluation of normal variants of circle of Willis at MRI, *International Journal Of Research In Medical Sciences*, 6(5), pp. 1617-1622.
7. Kızılgöz, V., Kantarcı, M. & Kahraman, Ş. (2022), Evaluation of Circle of Willis variants using magnetic resonance angiography, *Scientific Reports*, 12.
8. Li, Q., et al. (2011), A multidetector CT angiography study of Variations in the circle of Willis in a Chinese population, *Journal of Clinical Neuroscience*, 18(3), pp. 379-383.

9. Shatri Jeton, Cerkezi Selim, Bexheti Sadi (2018), MRA study of anatomical variations of circulus arteriosus cerebri in healthy adults of Kosova, *The Egyptian Journal of Radiology and Nuclear Medicine*, 49(4), pp. 1110-1118.
10. Son, Nguyen Tuan (2020), *Anatomy of the cerebral arteries through 256-channel computed tomography images*, PhD dissertation, Hanoi Medical University.

(Received: 30/12/2022 – Accepted: 06/02/2023)

---