

## A REVIEW OF PARACETAMOL: MECHANISM OF ACTION AND THE EFFECTS ON SPERMATOGENESIS

*Huynh Thi Thu Hien, Nguyen Hoang My Duyen, Nguyen Hoang Anh, Huynh Quang Hao, Nguyen Hoang Tin\**

*Can Tho University of Medicine and Pharmacy*

*\*Corresponding author: nhtin@ctump.edu.vn*

*Received: 23/05/2023*

*Reviewed: 14/6/2023*

*Accepted: 28/08/2023*

### ABSTRACT

*Nowadays, there are many factors causing the decrease of male reproductive function such as diet, routine, chemical, ... But some of them have not been paid appropriate attention to, especially the use of paracetamol, which has a significant negative effect on the reproductive process. In this study, we will summarize the results of several studies on the harmful effects of prolonged high-dose use of paracetamol on sperm number, quality, portability and testicular morphology in experimental animals and humans. The association between the long-term usage of paracetamol in chronic human diseases and their toxicity is highly concerned, especially the reproductive function. Their toxicity has increased more in adult male subjects, along with the introduction of studies on the use of high and long-term doses of paracetamol affecting reproductive quality. This review discusses the link between long-term usage of high doses of paracetamol and fertility as well as the effects of sex hormones in experimental animals and humans nowadays. As a result, paracetamol affects the reproductive system, impairing spermatogenesis and sperm quality. The amount of reproductive function damage, the dosage and duration of paracetamol usage are closely correlated. When groups of participants take paracetamol, numerous investigations in both experimental animals and humans have shown a decrease in sperm count and sperm motility as well as abnormalities in sperm morphology and testicular histology. Physicians have to exercise caution while treating patients with paracetamol and other related medications, especially men. Therefore, more studies should be done to determine the relationship between dosage, response, and treatment duration. When treating patients with decreased sexual function, medications that can prevent paracetamol toxicity should be used in conjunction with other medications. Especially, traditional medicine continues to play a significant part in the research and development of many new medicines despite the rapid advancement of contemporary medicine.*

**Keywords:** *paracetamol, spermatogenesis, testosterone, testis, infertility.*

### I. INTRODUCTION

Paracetamol (acetaminophen) is a common and widely used analgesic and antipyretic medicine that is available without a prescription in both mono- and multi-component combinations. It is the medicine of choice for patients who cannot be treated with non-steroidal anti-inflammatory drugs (NSAIDs), such as those with bronchial asthma, peptic ulcer disease, hemophilia, salicylate-sensitized people, children under the age of 12, pregnant women or breastfeeding women [1]. Not only in the hospital but also in life, the popular use of paracetamol also appeared with the aim of treating pain relief of acute diseases such as abdominal pain, headache, toothache, traumatic pain, etc., and is also suggested in the first treatment of chronic diseases such as osteoarthritis, degenerative spine, and spinal pain [2]. However, in recent years, the benefits of using paracetamol for chronic diseases have been questioned. Several studies have reported the toxicity of this drug with long-term

use and overdose in almost every organ in the human body [3]. Taking extra doses, repeating supra-therapeutic doses of paracetamol, and repeating therapy can all result in an unintentional overdose [4]. The cardiovascular, respiratory, renal, gastrointestinal, and central nervous systems, as well as potential effects on the offspring of pregnant women who consume paracetamol, have all been sources of concern [5]. In isolated paracetamol overdoses, there are rarely any immediate dangers to the airway, breathing, or circulation, but they are still possible. In exceptional circumstances, ingesting large amounts of paracetamol that result in extremely high serum paracetamol concentrations (typically above 800 mg/L or > 5000 mol/L) may be linked to lactic acidosis and an early decline in the level of consciousness [6]. With easy accessibility, paracetamol can be found and bought in any pharmacy without a prescription, posing many potential risks of abuse.

*Infertility* is a prevalent condition that affects around 70 million people globally. According to the World Health Organization, 50% of the problems with infertility are caused by the male factor, which affects 9% of couples globally [7]. Infertility is a disease defined by the inability to achieve a successful pregnancy after 12 months or more of appropriate, timed unprotected intercourse or therapeutic donor insemination [8]. In the United States, a 2019 study reported that 13.4% of women aged 15-49 have impaired fecundity, and 8.5% of married women aged 15-49 are infertile: 8.5% [9]. Among men in that age group, the rate of infertility is 9.4%, with 15.8% of married men aged 25 to 44 categorized as infertile or subfertile [10]. Infertility in men occurs from various causes that can be classified as disruption of testicular or ejaculatory function, hormonal disorders, and genetic disorders, which can lead to sperm without sperm or fertility but in low quantity or low quality [11]. Although there are numerous known causes of infertility, there is one recently recognized cause of male infertility that is due to adverse drug reactions (ADRs). Prolonged drug use in men may affect the activity of the hypothalamic-pituitary-gonadal (HPG) axis and thereby reduce fertility [7].

The issue of the use of analgesics and reproductive dysfunction is widely discussed and attracts much interest. Overusing of paracetamol increases the risk of side effects and complications in both humans and experimental animals. Overdose or long-term usage of paracetamol can lead to organ toxicity, including hepatotoxicity, urenal toxicity, and testicular toxicity, as well as changes in blood chemistry and reproductive parameters. When using high doses of paracetamol for a prolonged period, it can have an impact on both the quantity and quality of sperm. It alters the quality of semen, the morphology of sperm, and the structure of chromatin in sperm cells, thereby negatively affecting the male reproductive system [12]. Apart from paracetamol, there are other medicines that, when abused, can also cause toxicity to the male reproductive system, such as steroid anti-inflammatory drugs like prednisolone, and non-steroidal anti-inflammatory drugs (NSAIDs) like ibuprofen [7]. Not only in Vietnam but also globally, there is currently limited research on the toxicity of paracetamol on the male reproductive system. It can be said that paracetamol is more frequently used than other types of medicines. This is the explanation for why we chose paracetamol as the subject of our study this time. In this study, the focus was on demonstrating the toxicity of paracetamol and its effects on the testicles of both experimental animals and humans, exploring its impact on changes in histology, biochemical parameters, and testicular morphology, as well as the mechanisms of influence on spermatogenesis in laboratory animals through the results of other experimental studies.

## II. CONTENT

### 2.1 Structure and mechanism of paracetamol

N-acetyl-para-aminophenol is another name for paracetamol, also known as acetaminophen. In paracetamol (1,4), the nitrogen atom of an amide group (acetamide) and one hydroxyl group substitute the benzene ring core to form paracetamol [2]. Additionally, it also has two chemically identical isotopes, C<sub>8</sub>H<sub>9</sub>NO<sub>2</sub> which are 2- and 3-acetaminophen [13], as shown in Figure 1.

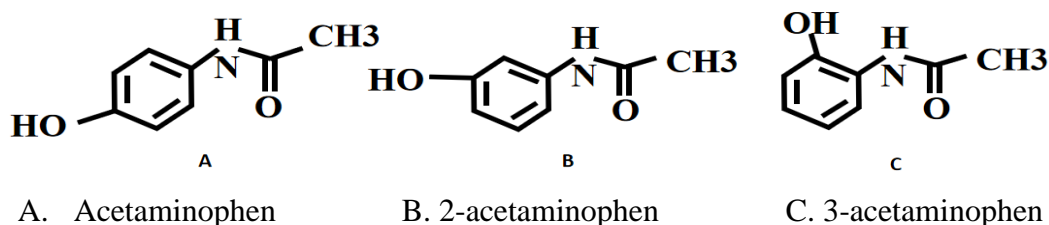


Figure 1. Paracetamol and isomers

(Perlovich G.L., Volkova T.V., Manin A., and Bauer-Brandl A. Influence of Position and Size of Substituents on the Mechanism of Partitioning: A Thermodynamic Study on Acetaminophens, Hydroxybenzoic Acids, and Parabens. *AAPS PharmSciTech*, 2008.9(1), 205-216) [13]

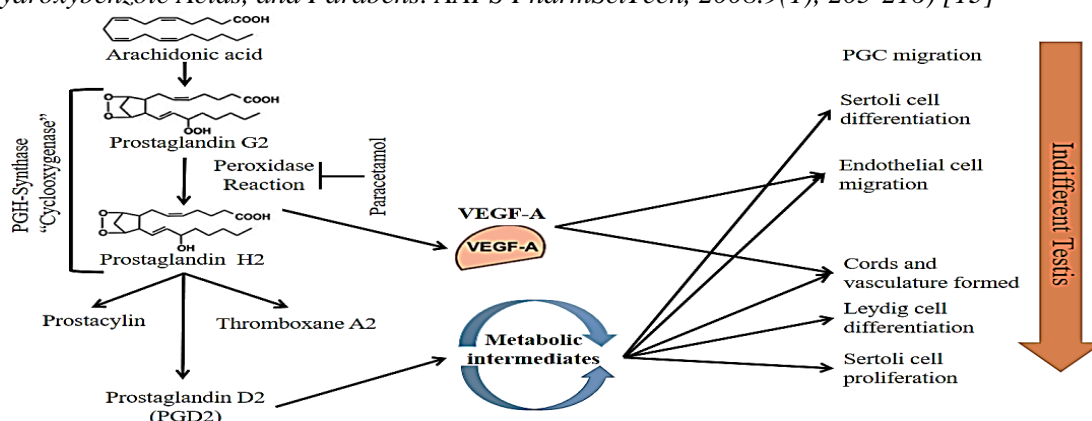


Figure 2. Paracetamol's effect on the indifferent testis

(Sargent K.M., McFee R.M., Gomes R.S., and Cupp A.S. Vascular endothelial growth factor A: just one of multiple mechanisms for sex-specific vascular development within the testis? *Journal of Endocrinology*, 2015.227(2) [14] and Hinz B., and Brune K. Paracetamol and cyclooxygenase inhibition: Is there a cause for concern? *Annals of the Rheumatic Diseases*, 2013.71(1), 20-25) [15]

The hydroxyl oxygen lone pair, the benzene pi cloud, the nitrogen lone pair, the orbital on the carbonyl carbon, and the hydroxyl oxygen lone pair are all intertwined in the paracetamol molecule. The benzene ring is extremely susceptible to electrophilic aromatic substitution due to the presence of two activating groups. Oxygen and nitrogen atoms lose a lot of their basic value as a result of this conjugation. Acid is changed into a hydroxyl group through the delocalization of the charge created on the phenoxide anion [2]. The complicated "redox" and peripheral (COX inhibition) and central (COX, serotonergic descending neuronal pathway, L-arginine/NO pathway, cannabinoid system) antinociception processes and mechanisms are all involved in the action of paracetamol [1]. The VEGF-A pathway and the intermediate metabolic pathway are the two main pathways that comprise the

prostaglandin synthase system. These pathways impact the various Sertoli cells, endothelial cells, and Leydig cells as well as the testis and male reproductive systems (**Figure 2**).

Arachidonic acid (AA) is converted by prostaglandin H synthase (PGHS), also known as cyclooxygenase (COX) within COX-1 and COX-2 in **Figure 2**, into prostaglandin H (PGH<sub>2</sub>), inhibited by paracetamol [14]. In particular, paracetamol is likely to function as a factor reducing a ferrous protoporphyrin IX radical cation ( $Fe^{4+} = OPP^{*+}$ ) within the peroxidase site of the COX enzyme.  $Fe^{4+} = OPP^{*+}$  generates tyrosine radicals in place of the enzyme COX, which are necessary for catalyzing the AA oxidation reaction and preventing PGH<sub>2</sub> from being produced from AA [1]. Paracetamol, on the other hand, might act as a reducing agent at the peroxidase site by squelching a radical that's in charge of the spread of the cyclooxygenase reaction [15].

## 2.2. The adverse impacts on testosterone

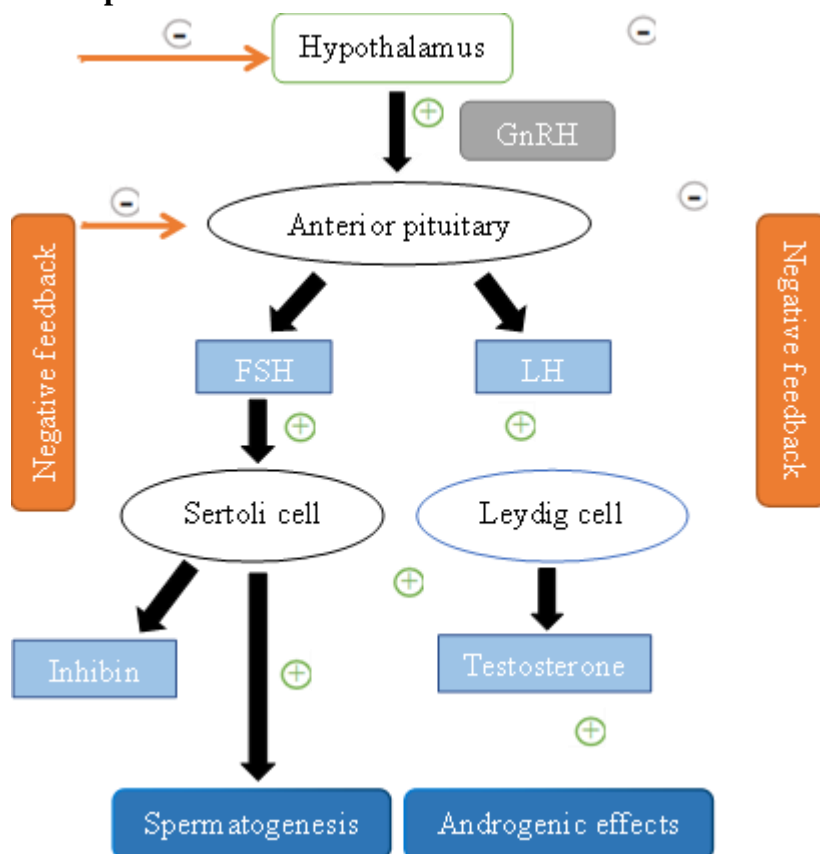


Figure 3. Hypothalamic-pituitary-testicular axis negative feedback regulation mechanism (Mona. *Hormonal Regulation of Male Reproductive System (Human)*. 2020. <https://biologicalhelp.blogspot.com>) [20]

Analgesic-affecting substances have recently been considered potential endocrine system disruptors due to their high degree of structural similarity to specific endocrine-disrupting compounds (EDCs). According to study findings, EDCs inhibited the PG pathway in the mouse Sertoli cell line and decreased the amount of PG synthesized in ex vivo rat testes, which reduced the amount of testosterone produced [16]. Additionally, it was discovered that both in utero and in vitro, mild analgesics have anti-androgenic effects in the rat fetal testis

[17]. Endocrine disturbances may be related to the direct anti-prostaglandin activity of the drug and the inhibition of PGE2 and PGF2a production in the rat fetal testis [18].

One study showed the negative effects of paracetamol on the hypothalamic-pituitary-testicular axis. The secretion of male sex hormones is regulated through the negative feedback mechanism of the hypothalamic-pituitary-testicular axis. In **Figure 3**, hypothalamic changes are associated with changes in the hypothalamus and changes in levels of catecholamines and amino acids. A significant decrease in glutamic acid levels was also observed in the group of rats treated with paracetamol at a dose of 5 mg. These findings show that paracetamol significantly affects dopaminergic and noradrenergic neurotransmission and changes the glutamic acid concentration in the hypothalamus, one of the hypothalamic-pituitary-testicular axis valuable components [19], [20].

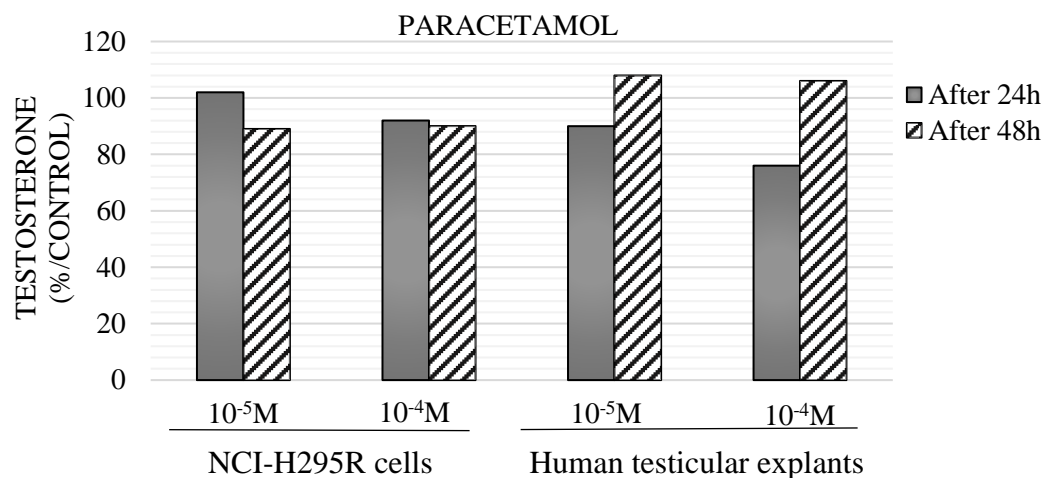


Figure 4. Time and the dependent dose effects  $10^{-5}M$  and  $10^{-4}M$  paracetamol by NCI-H295R cells and human testicular explants

(Albert O., Desdoits-Lethimonier C., Lesne L., Legrand A., and Guille F., et al. Paracetamol, aspirin and indomethacin display endocrine- disrupting properties in the adult human testis in vitro. *Hum Reproduction*, 2013.28(7), 1890- 1898) [17]

Another research has recently shown that several moderate analgesics display endocrine-disrupting effects in the adult human testis in vitro, as assessed by analyzing organ-cultured adult human testis and the NCI-H295R steroid-producing human cell line. According to research, mild analgesics directly affect the adult testes endocrine system, preventing the production of testosterone in human cell lines and cultured adult testes (NCI-H295R). The treated NCI-H295R human adrenocortical cell line or adult human testis explants were cultured with  $10^{-4} M$  or  $10^{-5} M$  paracetamol for 24 hours or 48 hours. According to research, paracetamol exposure at concentrations of  $10^{-5} M$  and  $10^{-4} M$  in human testicles significantly decreased testosterone secretion by 18% and 30%, respectively, after 24 hours. The study results are depicted in **Figure 4**. Human testes exposed to paracetamol concentrations of  $10^{-5} M$  and  $10^{-4} M$  significantly reduced testosterone secretion after 24 hours by 18% and 30%, respectively. However, after the next 48 hours, the reduction did not reach statistical significance. In the NCI-H295R cell line, paracetamol exposure at concentrations of  $10^{-5} M$  inhibited the production of testosterone by 13% after 48 hours, but

the effect was not statistically significant after 24 hours. In contrast, paracetamol significantly reduced testosterone at a concentration of  $10^{-4}$  M after 24 hours (by -10%) but not after 48 hours. This demonstrates that the antiandrogen effect on testicular specimens for the drug doses decreased between 24 and 48 hours after exposure [17].

In a study of several anti-androgen substances in the testes of fetal rats, paracetamol significantly reduced the amount of testosterone in male rats. The study demonstrated that paracetamol reduced the generation of testosterone by Leydig cells at dosages ranging from 0.1  $\mu$ m to 100  $\mu$ m in a 3-day ex vivo organotypic model system based on rat testes at gestational day 14.5. The levels of testosterone produced by the fetal Leydig cells were approximately 10-50% lower than the controls at all paracetamol concentrations (0.1-100  $\mu$ m) used. According to previous findings, in this fetal testis culture system, the anti-androgenic effects of paracetamol were clearly not correlated with those of PGD2. These results are also in line with a rat study from prior showing PGs decrease LH-induced testosterone synthesis by rat Leydig cells in culture [18].

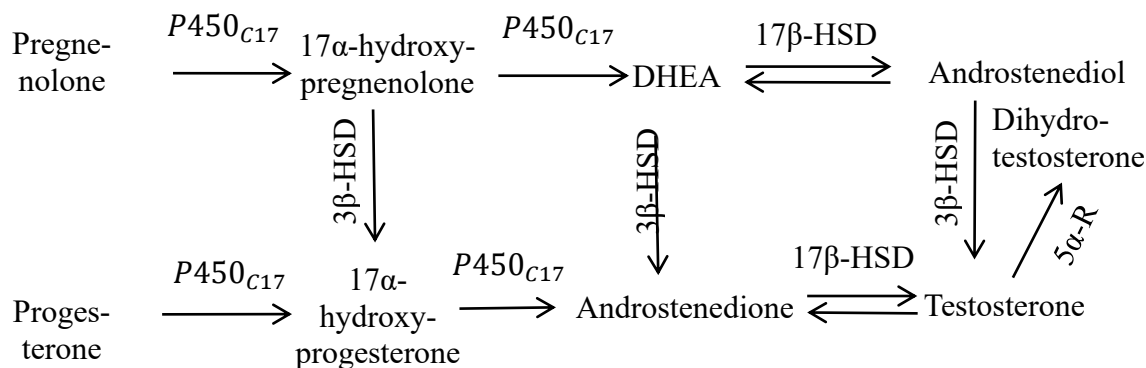


Figure 5. Steroid biosynthesis pathways in Leydig cells' smooth endoplasmic reticulum (Kotula-Balak M., Hejmej A., and Bilińska B. *Hydroxysteroid Dehydrogenases-Localization, Function and Regulation in the Testis*, 2012.370) [21]

In a xenograft study, researchers grafted human fetal testicles into castrated host mice, then exposed them to therapeutic doses of acetaminophen for 7 days. This resulted in a significant decrease in plasma testosterone (45% decrease;  $P = 0.025$ ) and seminal vesicle weight (a biomarker of androgen exposure; 18% decrease;  $P = 0.005$ ) in host mice castrated with foreign testicular grafts from human fetuses, while exposure to acetaminophen for just one day did not change either parameter. Subsequently, in *in utero* exposure studies in mice, it was shown that the reduction in testosterone induced by acetaminophen might result from decreased expression of the major steroidogenic enzymes (CYP11A (Cytochrome P450 11A1), CYP17A1 (CYP11A (Cytochrome P450 11A1), and Cytochrome P450 17A1) via the steroid biosynthesis of Leydig cells depicted in **Figure 5**, where the heme-containing protein cytochrome P450 and hydroxysteroid dehydrogenase (HSD) are the two major steroidogenic enzymes [21]. The study's findings suggest that frequent usage of acetaminophen (one week) may inhibit the creation of fetal testosterone, though the causes of the inhibition are not yet fully understood [22].

A growing body of epidemiological and experimental evidence suggests that paracetamol may be an endocrine disruptor of the male reproductive system, altering the

generation of testicular hormones. Paracetamol has previously been found to affect steroid synthesis by the human steroidogenic adrenocortical cell line NCI-H295R, which is consistent with this. In line with this, we discovered a dose-dependent decline in 17-hydroxyprogesterone, androstenedione, and testosterone with a parallel rise in estrogens. Our research on the effects on steroidogenesis leads us to hypothesize that paracetamol's ability to reduce testosterone may be caused by the stimulation of CYP19 or, more likely, the inhibition of CYP17A1 [23].

Table 1. Paracetamol affects the sulfation of some androgenic steroid hormones, such as pregnenolone and progesterin

Pathway	Metabolite	Training and test sets combined (n = 455)	
		Direction change	p-value
Androgenic steroids	Androstenedione (3 betas,17 betas) disulfate (1)	↓	3.74E-04
Androgenic steroids	Androstenedione (3 betas, 17 betas) disulfate (2)	↓	8.53E-06
Pregnenolone steroids	Pregnenolone sulfate	↓	1.50E-04
Pregnenolone steroids	21-Hydroxypregnenolone disulfate	↓	2.77E-05
Progesterin steroids	Pregnendione disulfate C <sub>21</sub> H <sub>34</sub> O <sub>8</sub> S <sub>2</sub>	↓	1.32E-05

Suffixes (1) and (2): indicate different sulfation sites on the molecular structure.

(Cohen I.V., Cirulli E.T., Mitchell M.W., Jonsson T.J., and Yu J., et al. *Acetaminophen (Paracetamol) Use Modifies the Sulfation of Sex Hormones. EbioMedicine, 2018.28, 316-323*) [24]

In one research, a model that determined metabolomic variations between samples from 455 people who used acetaminophen and those who did not was trained and evaluated. Acetaminophen was used as a classifier for sPLS-DA (sparse partial least squares-discriminant analysis) machine learning. The drop in numerous sulfated sex hormones caused the signal in the sPLS-DA. In particular, the effects of acetaminophen usage on steroid hormones with sulfonated hydroxyl groups were substantiated by four highly correlated products, androstenedione (3 betas, 17 betas) disulfate, pregnenolone sulfate, 21-hydroxypregnenolone disulfate, and pregnendione disulfate (**Table 1**). The effect of acetaminophen usage on steroid metabolism was profiled by combining the test and training groups to reveal the complete range of activity. The range of activity for a number of sulfated hormones is clearly defined. Cortisol, cortisone, corticosterone, epiandrosterone sulfate, and androsterone sulfate, on the other hand, were unaffected. In conclusion, the use of sacetaminophen particularly lowers the levels of a distinct group of sulfated sex hormones [24].

All of the aforementioned research shows that direct exposure to paracetamol can cause a wide range of endocrine abnormalities in the male testicles. Several investigations have discovered and proven that paracetamol has a negative impact on testosterone

production. Although the mechanism is obscure and debatable, it has been suggested that males should use paracetamol with caution and attention.

### 2.3 The adverse impacts on seminal parameters

High doses of paracetamol seem to impact the male reproductive system, altering the semen quality, specifically morphology, and, consequently, the capacity to fertilize. By inhibiting testosterone synthesis, causing oxidative stress, triggering spermatocyte apoptosis, decreasing nitric oxide production, and inhibiting prostaglandin synthesis, paracetamol may have an influence on sperm quality. The spermatids contained unevenly compacted chromatin and particularly well-developed rough endoplasmic reticular and Golgi complexes [12].

A study conducted in male rats (*Albino Rats*) with 42 days of treatment with paracetamol (7.5 mg/kg body weight) caused an insignificant change in the viability of sperm but significantly reduced sperm count, a significant decrease in sperm motility as well as a significant increase in the proportion of morphologically abnormal sperm cells compared to the control group described in **Figure 6** and **Figure 7** [25].

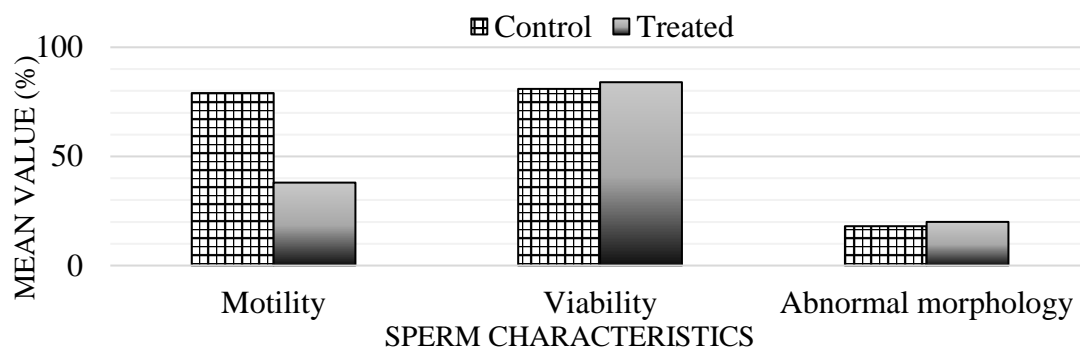


Figure 6. Spermogram showing the effect of 42 days of treatment of rats with 7.5 mg/kg body weight paracetamol on sperm characteristics

(Oyedeji K.O., Bolarinwa A.F, and Ojeniran S.S. *Effect of Paracetamol (Acetaminophen) On Haematological and Reproductive Parameters in Male Albino Rats. IOSR Journal of Pharmacy and Biological Sciences, 2013.4(6), 65-70*) [25]

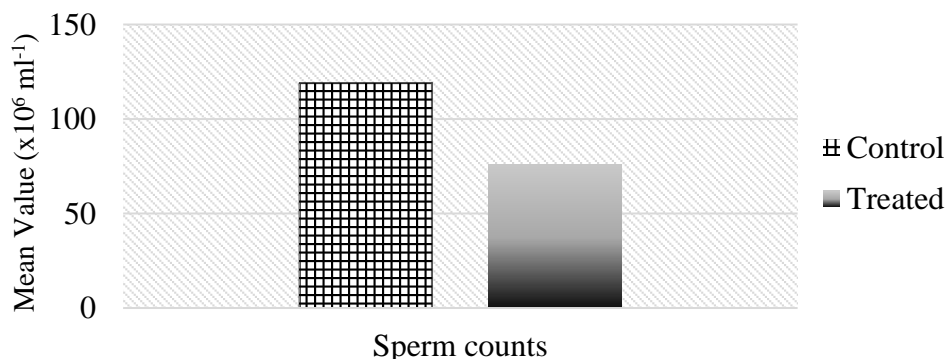
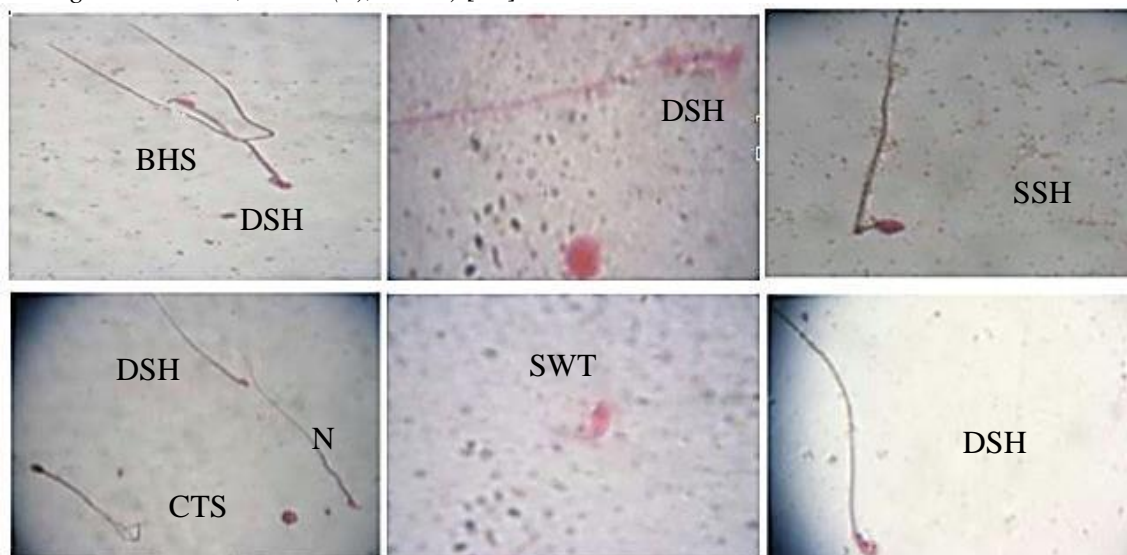


Figure 7. Spermogram showing the effect of 42 treatments of rats with 7.5 mg/kg body weight of paracetamol on sperm counts



(Oyedeji K.O, Bolarinwa A.F, and Ojeniran S.S. Effect of Paracetamol (Acetaminophen) On Haematological and Reproductive Parameters in Male Albino Rats. IOSR Journal of Pharmacy and Biological Sciences, 2013.4(6), 65-70) [25]



(N) Normal sperm;  
 (BHS) Blunt hook sperm;  
 (SWT) Sperm without tails;  
 (CTS) Coiled tail sperm;  
 (DSH) Defective head;  
 (SSH) Swollen sperm head.

Figure 8. Effect of PAR on sperm abnormalities after using a high dose (5 g/kg) of PAR (Qader S.W., and Othman G.O. Cytological and Histological Effect of Paracetamol on the Testis and Liver in Albino Mice *Mus musculus*. Journal of Zankoy Sulaimani - Part A, 2014.16(4)) [26]

This might be because paracetamol has the ability to interfere with spermatogenic processes in the seminiferous tubules or epididymal functions, which could change spermatogenesis. This also suggests that the drug may permeate the blood-testis barrier, altering the micro-environment of the seminiferous tubules, as it has been reported that chemical agents reduce sperm motility due to their ability to permeate the blood-testis barrier [25].

Another study in Albino mice *Mus musculus* showed that a single dose of paracetamol (5 g/kg) induced various abnormalities in mice's sperm morphology, such as blunt hook sperm (BHS), sperm without tails (SWT), coiled tail sperm (CTS), defective head sperm (DHS) and swollen head sperm (SHS) as shown in **Figure 8**. This study also showed a significant reduction in both sperm count and motility by multiple mechanisms causing shedding, deformation of the seminiferous tubules, and fragmentation of Sertoli cells - which play a major role in providing nutrition and support for the spermatid cells. As a result, it reduces sperm quality as well as sperm density and motility [26].

There is a hypothesis that paracetamol is N-hydroxylated by cytochrome P450 to form NAPQI (N-acetyl-p-benzoquinone imine), a strong oxidizing substance that causes cell necrosis and damages organs such as kidneys, pancreas, testicles...NAPQI will act as an activator of oxidative stress and affect the structural parts of sperm, especially the tail region, causing a decrease in motility and patterns of abnormal motility in sperm [27].

## 2.4 The adverse impacts on test

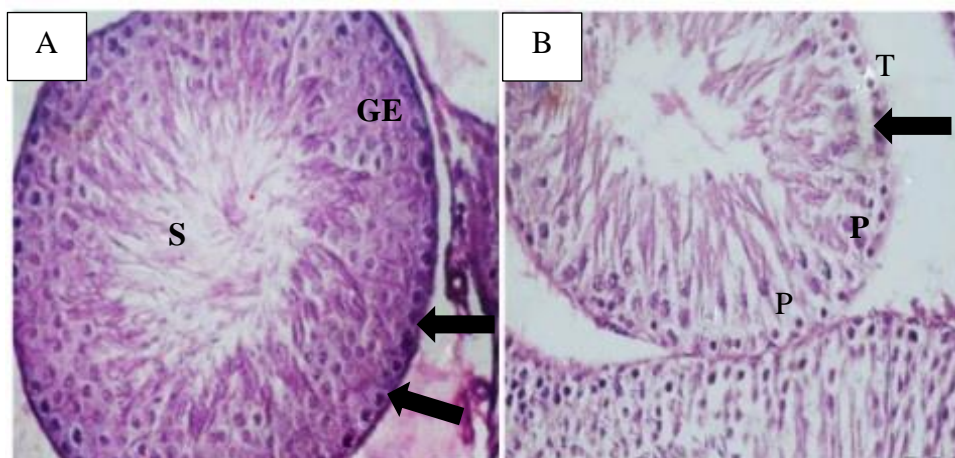


Figure A  
GE: Sertoli cell  
S: Sperm

Figure B  
Arrow: spermatogenic cysts  
T: separated and ruptured basement the membrane of the germinal epithelial cells  
P: degenerated germ cells with pyknotic nuclei

Figure 9. Testis structure before and after paracetamol treated

(Khayyat. L.I. *Extra Virgin Olive Oil Protects the Testis and Blood from the Toxicity of Paracetamol (Overdose) in Adult Male Rats. Biology (Basel), 2021.10(10), 1042*) [12]

Many preclinical studies have established that paracetamol is effective as an endocrine disruptor that produces significant changes in testicular morphology. Similar research indicated that giving paracetamol to experimental animals for 50 days caused various alterations in the testicular structure, including altered seminiferous tubules and a few degraded tubules [12].

A similar study suggested that when rats were treated with paracetamol for 15 consecutive days, that caused deformation and toxicity in the testicles, manifested by having divided and broken basement membranes of the germinal epithelial cells and degraded germ cells with pyknotic nuclei. A loss of normal testicular structure was clearly observed, with pronounced disorganized testicular tubes (**Figure 9**) [12].

Light microscopy examination of control rat testis sections confirmed the typical characteristic features of normal seminiferous tubules, including normal spermatogenic cells, Sertoli cells, and spermatozoa (**Figure 9A**). When testis sections from animals treated with paracetamol for 15 days were compared to controls, they revealed testicular deformation. The normal testicular structure is clearly lost, with disordered spermatogenic cysts with divided and torn basement membranes of germinal epithelial cells and degraded germ cells with pyknotic nuclei (**Figure 9B**) [12].

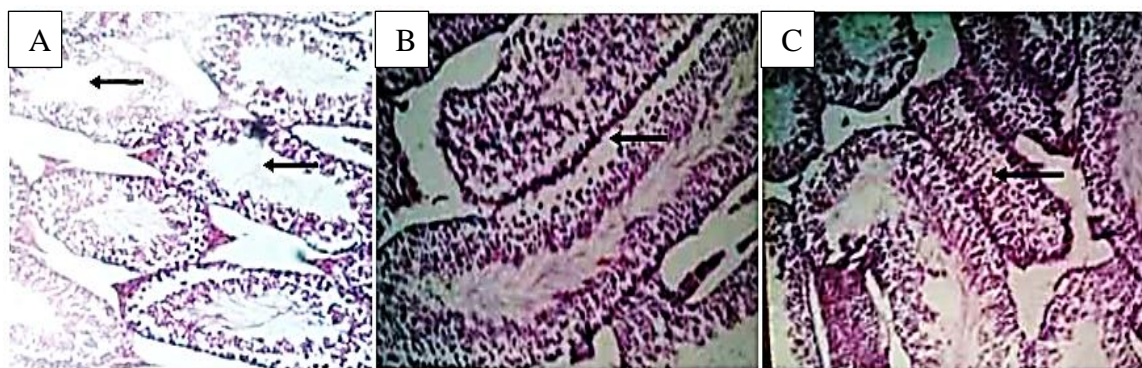


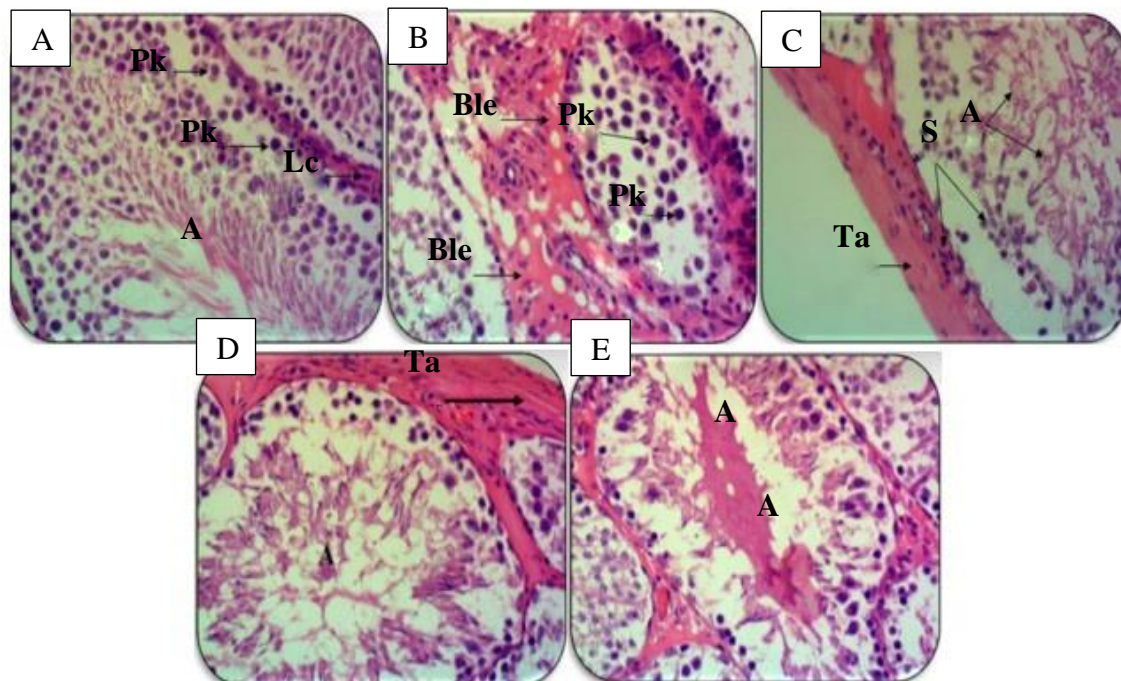
Figure A shows atrophy of some seminiferous tubules with a small number of sperm cells  
 Figure B shows loss of contact between basal cells due to Sertoli cell fragmentation  
 Figure C shows the disruption of some seminiferous cells which contained few cells, and had considerably smaller diameters than normal tubules

Figure 10. Modified testicular structure after the use of high doses of paracetamol (5 g/kg) (*Qader S.W., and Othman G.O. Cytological and Histological Effect of Paracetamol on the Testis and Liver in Albino Mice *Mus musculus*. Journal of Zankoy Sulaimani - Part A, 2014.16(4)) [26]*

A different study in healthy adult mice *Mus musculus* aged 6-8 weeks old showed that a single dose of paracetamol (5 g/kg) administered to male mice resulted in abnormal morphological and degenerative changes in some sperm tubes, fragmentation of Sertoli cells, abnormal chromosomes in the nucleus and changes in sperm structure [26]. This study indicated that after using a high dose for 15 days of paracetamol administration in laboratory mice, it influenced spermatocytes and augmented the frequency of sperm via modified chromatin structure. When adult healthy *Mus musculus* mice were administered orally in doses of 2 g/kg and 5 g/kg, it was shown that the use of paracetamol in a small amount (2 g/kg) did not result in significant morphological modifications. Meanwhile, a high dose (5 g/kg) of PAR formed many toxic indications such as nausea, vomiting, shivering, and death. When the researcher was discharged for the study, they recorded the use of high doses (5 g/kg) of paracetamol, which induced testicular atrophy of numerous seminiferous tubules, some of which were devoid of germinal epithelium and primarily contained Sertoli cells with a little sperm cell (**Figure 10A**); the loss of interaction between basal cells appears to be the result of Sertoli cell fragmentation (**Figure 10B**); some seminiferous tubules that had significantly smaller widths than usual tubules (**Figure 10C**) [26]. Defects in the seminal epithelium cells that support and care for the spermatogenic cells result in spermatogenic cell loss, which may give rise to tissue destruction and infertility [26].

Another study of paracetamol's effect on fertility was also conducted in *Rattus norvegicus*. When paracetamol was given in tubular doses (1000 mg/kg) for six consecutive weeks, there were many changes in the morphology, structure, and function of the testicles, as follows. The spermatogenesis is completely stopped, with shrinkage and hyperplasia of Leydig cells with pyknosis of the primary spermatogonia nucleus (**Figure 11A**), bleeding between the seminiferous tubules (Ble) and pyknosis of the primary spermatogonia nucleus (**Figure 11B**), disconnection of spermatogenic cells from spermatogonia cells and expansion of the tunica albuginea (**Figure 11C**), the developmental stages of spermatogenesis are lost, the decrease and abnormality of spermatogenic cells, and the expansion of the tunica

albuginea (**Figure 11D**), the seminiferous tubule components were exfoliated as cellular debris and collected as an acid-colored material (**Figure 11E**) [28].



- A. showing stop of spermatogenesis (A) and atrophy and hyperplasia of Leydig cells (Lc) with pyknosis of nucleus of primary spermatogonia (pk)
- B. showing the presence of bleeding between the seminiferous tubules (Ble) and pyknosis of the nucleus of primary spermatogonia (pk)
- C. showing the stop of the spermatogenesis (A) and the separation of the spermatogenic cells from the spermatogonia cells (S) and the tunica albuginea thickens (Ta)
- D. showing complete loss of spermatogenesis (A) and tunica albuginea thickened (Ta)
- E. shows exfoliation of the seminiferous tubule components in the form of cellular debris with aggregated as an acid-colored material (A)

Figure 11. Testis histological on microscope after using a dose of 1000 mg/kg in 6 weeks (Alkhafaji N.T., and Shaher W.S. *The protective effect of common fig (Ficus carica L.) leaves extract on testes of white rats (Rattus norvegicus) against paracetamol (Acetaminophen) drug.* Tikrit Journal of Pure Science, 2020.25(6)) [28]

A substantial reduction in blood testosterone and seminal quality impairment was seen in the group given high repeated therapeutic doses of paracetamol, which generated various alterations and harmfully influenced the histological structure of the seminiferous tubules. The study indicates that paracetamol may lead to reproductive damage and should be administered cautiously, especially when large extended doses are indicated [29].

The morphological changes of *Wistar* rat testicles were studied in animals given paracetamol. A single dose of 4.4 mmol/kg paracetamol was given to the rats. The rats were perfused with Karnovsky's fixative and processed for optical and electron microscopy after 5, 10, and 50 days. Some altered seminiferous tubules, as well as a few degenerating tubules, were discovered. Sertoli cells appeared fragmented within the tubules, whereas spermatids

featured abnormally well-developed rough endoplasmic reticulum and Golgi complexes, as well as unevenly compacted chromatin [30].

### III. RESEARCH PROSPECTS

The above study reports carried out on a group of subjects using the drug at specific doses and periods, monitored and statistically recorded should have considerable reliability, hence the possible clinical practice of the drug in men. We should conduct further research to establish a relationship between dosage, response and treatment duration to find out the maximum dose and duration of treatment without causing this side effect. Medicines that can inhibit paracetamol toxicity should be used in combination with treatment and should be considered and replaced by other medicines in patients with reduced sexual function. Along with the rapid development of modern medicine, traditional medicine still plays an important role in the research and development of many new medicines. Among them, interest in herbal medicine and how it is used in the treatment of infertility has increased in recent decades, possibly due to the availability of antioxidants in plants along with their effectiveness in fertility treatment. Currently, some foods have also been studied for improving testicular damage and protecting reproductive function from the toxicity of male paracetamol, such as fig (*Ficus carica* L.) leaves extract, curcumin (a dietary polyphenol from the roots and rhizomes of the spice *curcumin longa*), extra virgin olive oil, ... [12], [28], [29].

### IV. CONCLUSIONS

In summary, paracetamol has an impact on the reproductive system, damaging spermatogenesis and sperm quality. There is a close relationship between dosage, duration of use of paracetamol, and the degree of damage to reproductive function. Many experiments have demonstrated a decrease in sperm count and sperm motility as well as abnormalities in sperm morphology and testicular histology in groups of subjects using paracetamol - studies in both experimental animals and humans. Therefore, we need to be careful when using paracetamol as well as similar drugs in treatment, especially in men.

### REFERENCES

1. Józwiak-Bebenista M., and Nowak J.Z. Paracetamol: Mechanism of action, applications and safety concern. *Acta Poloniae Pharmaceutica - Drug Research*. 2014.71, 11- 23.
2. Freo U., Ruocco C., Valerio A., Schiavagnoli I., and Nisoli E. Paracetamol: A Review of Guideline Recommendations. *Journal of Clinical Medicine*. 2021.10(15), 3420. <https://doi.org/10.3390/jcm10153420>.
3. Banihani S.A. Effect of paracetamol on semen quality. *Andrologia*. 2018.50(1). <https://doi.org/10.1111/and.12874>.
4. Saragiotto B.T., Shaheed A.C., Maher C.G. Paracetamol for pain in adults. *The BMJ*. 2019. 367, 16693. <https://doi.org/10.1136/bmj.l6693>.
5. McCrae J.C., Morrison E.E., MacIntyre I.M., Dear J.W., and Webb D.J. Long-term adverse effects of paracetamol - a review. *British Journal of Clinical Pharmacology*. 2018.84(10), 2218-2230. <https://doi.org/10.1111/bcp.13656>.
6. Chiew A.L., Fountain J.S., Graudins A., Isbister G.K. and Reith D., et al. Summary statement: New guidelines for the management of paracetamol poisoning in Australia and New Zealand. *The medical journal of Australia*. 2015.203, 215-218. <https://doi.org/10.5694/mja15.00614>.
7. Samplaski M.K., and Nangia A.K. Adverse effects of common medications on male fertility. *Nature Review Urology*. 2015.12, 401-413. <https://doi.org/10.1038/nrurol.2015.145>.

8. Practice Committee of American Society for Reproductive Medicine. Definitions of infertility and recurrent pregnancy loss: a committee opinion. *Fertility and Sterility*. 2013.99(1), 63. <https://doi.org/10.1016/j.fertnstert.2012.09.023>.
9. Centers for Disease Control and Prevention. Infertility. 2022. <https://www.cdc.gov/nchs/fastats/infertility.htm>.
10. Chandra A., Copen C.E., and Stephen E.H. Infertility and impaired fecundity in the United States, 1982-2010: data from the National Survey of Family Growth. *Natl Health Stat Report*. 2013.67, 1-19.
11. Centers for Disease Control and Prevention. Infertility. What causes infertility in men?. 2023. <https://www.cdc.gov/reproductivehealth/infertility/index.htm>.
12. Khayyat. L.I. Extra Virgin Olive Oil Protects the Testis and Blood from the Toxicity of Paracetamol (Overdose) in Adult Male Rats. *Biology (Basel)*. 2021.10(10), 1042. <https://doi.org/10.3390/biology10101042>.
13. Perlovich G.L., Volkova T.V., Manin A., and Bauer-Brandl A. Influence of Position and Size of Substituents on the Mechanism of Partitioning: A Thermodynamic Study on Acetaminophens, Hydroxybenzoic Acids, and Parabens. *AAPS PharmSciTech*. 2008.9(1), 205-216. <https://doi.org/10.1208/s12249-008-9033-0>.
14. Sargent K.M., McFee R.M., Gomes R.S., and Cupp A.S. Vascular endothelial growth factor A: just one of multiple mechanisms for sex-specific vascular development within the testis?. *Journal of Endocrinology*. 2015.227(2), 31-50. <https://doi.org/10.1530/JOE-15-0342>.
15. Hinz B., and Brune K. Paracetamol and cyclooxygenase inhibition: Is there a cause for concern?. *Annals of the Rheumatic Diseases*. 2013.71(1), 20-25. <https://doi.org/10.1136/ard.2011.200087>.
16. Kristensen D.M., Skalkam M.L., Audouze K., Lesné L., and Desdoits-Lethimonier C., et al. Many putative endocrine disruptors inhibit prostaglandin synthesis. *Environ Health Perspect*, 2011.119(4), 534-41. <https://doi.org/10.1289/ehp.1002635>.
17. Albert O., Desdoits-Lethimonier C., Lesne L., Legrand A., and Guille F., et al. Paracetamol, aspirin and indomethacin display endocrine disrupting properties in the adult human testis in vitro. *Hum Reproduction*. 2013.28(7), 1890- 1898. <https://doi.org/10.1093/humrep/det112>.
18. Kristensen D.M., Lesné L., Le Fol V., Desdoits- Lethimonier C., and Dejucq-Rainsford N., et al. Paracetamol (acetaminophen), aspirin (acetylsalicylic acid) and indomethacin are anti-androgenic in the rat foetal testis. *International Journal of Andrology*. 2012.35(3), 377-384. <https://doi.org/10.1111/j.1365-2605.2012.01282.x>.
19. Holm J.B., Chalmei C., Modick H., Jensen L.S., and Dierkes G. Aniline Is Rapidly Converted Into Paracetamol Impairing Male Reproductive Development. *Toxicological Science*. 2015.148(1), 288-298. <https://doi.org/10.1093/toxsci/kfv179>.
20. Mona. Hormonal Regulation of Male Reproductive System (Human). 2020. <https://biologicalhelp.blogspot.com/2020/04/hormonal-regulation-of-male.html>.
21. Kotula-Balak M., Hejmej A., and Bilińska B. Hydroxysteroid Dehydrogenases - Localization, Function and Regulation in the Testis. 2011.3342. <https://doi.org/10.5772/47740>.
22. Driesche S. V. D., Macdonald J., Anderson R. A., and Johnston Z. C., et al. Prolonged exposure to acetaminophen reduces testosterone production by the human fetal testis in a xenograft model. *Science translational medicine*.2015.7(288), 288. <https://doi.org/10.1126/scitranslmed.aaa4097>.
23. Blecharz-Klin K., Wawer A., Pyrzanowska J., Piechal A., and Jawna-Zbońska K., et al. Hypothalamus - Response to early paracetamol exposure in male rats offspring. *International Journal of Developmental Neuroscience*. 2019.76, 1-5. <https://doi.org/10.1016/j.ijdevneu.2019.05.004>.
24. Cohen I.V., Cirulli E.T., Mitchell M.W., Jonsson T.J., and Yu J., et al. Acetaminophen (Paracetamol) Use Modifies the Sulfation of Sex Hormones. *Ebiomedicine*.2018.28, 316-323. <https://doi.org/10.1016/j.ebiom.2018.01.033>.

25. Oyedeji K.O., Bolarinwa A.F, and Ojeniran S.S. Effect of Paracetamol (Acetaminophen) On Haematological and Reproductive Parameters in Male *Albino* Rats. *IOSR Journal of Pharmacy and Biological Sciences*. 2013. 4(6), 65-70. <https://doi.org/10.9790/3008-0466570>.
  26. Qader S.W., and Othman G.O. Cytological and Histological Effect of Paracetamol on the Testis and Liver in Albino Mice *Mus musculus*. *Journal of Zankoy Sulaimani - Part A*. 2014.16(4).[https://www.researchgate.net/publication/314878765\\_Cytologicaal\\_and\\_Histologica\\_1\\_Effect\\_of\\_Paracetamol\\_on\\_the\\_Testis\\_and\\_Liver\\_in\\_Albino\\_Mice\\_Mus\\_musculus](https://www.researchgate.net/publication/314878765_Cytologicaal_and_Histologica_1_Effect_of_Paracetamol_on_the_Testis_and_Liver_in_Albino_Mice_Mus_musculus).
  27. Mannucci A., Argento F.R., Fini E., Coccia M.E., and Taddei N., et al. The Impact of Oxidative Stress in Male Infertility. *Front Mol Biosci*, 2022.8, 4. <https://doi.org/10.3389%2Ffmolb.2021.799294>.
  28. Alkhafaji N.T., and Shaher W.S. The protective effect of common fig (*Ficus carica* L.) leaves extract on testes of white rats (*Rattus norvegicus*) against paracetamol (Acetaminophen) drug. *Tikrit Journal of Pure Science*. 2020.25(6). <https://doi.org/10.33899/rjs.2021.167682>.
  29. El-Maddawy Z.K., and El-Sayed Y.S. Comparative analysis of the protective effects of curcumin and N-acetyl cysteine against paracetamol-induced hepatic, renal, and testicular toxicity in *Wistar* rats. *Environmental Science and Pollution Research*. 2018.25, 3468-3479. <https://doi.org/10.1007/s11356-017-0750-3>.
  30. Yano C.L., and Dolder. Rat testicular structure and ultrastructure after paracetamol treatment. *Contraception*. 2002.66, 463-467. [https://doi.org/10.1016/s0010-7824\(02\)00407-9](https://doi.org/10.1016/s0010-7824(02)00407-9).
-